

Safety and Efficacy of a Novel Diffractive Lens Array Using a Picosecond 755 nm Alexandrite Laser for Treatment of Wrinkles

Robert A. Weiss, MD, FAAD,^{1*} David H. McDaniel, MD, FAAD,² Margaret A. Weiss, MD, FAAD,¹ Anne Marie Mahoney, MD, FAAD,¹ Karen L. Beasley, MD, FAAD,¹ and Christian R. Halvorson, MD, FAAD¹

¹MD Laser Skin and Vein Institute, Baltimore, Maryland

²McDaniel Institute, Virginia Beach, Virginia

Introduction: Picosecond lasers have been reported to be effective for removal of tattoo pigment. This prospective study evaluated the efficacy and safety of the treatment of peri-oral and -ocular wrinkles using a novel diffractive lens array coupled with a picosecond 755 nm alexandrite laser.

Methods: Forty female subjects presenting with wrinkles from photodamage were enrolled in an IRB approved study. Subjects received four picosecond diffractive lens array treatments to the full face at 1 month intervals. Six subjects were biopsied (two subjects at 1 month, two subjects at 3 months, and two subjects at 6 months). Digital photographic images were taken at 1, 3, and 6 months post-final treatment visits. Images were graded by blinded physicians for fine lines/wrinkles, erythema, dyschromia, and global improvement. Data on discomfort level, satisfaction, and side effects were recorded.

Results: Overall blinded physician rated global improvement ranged from improved to much improved at 1-, 3-, and 6-month time points. At baseline the average Fitzpatrick wrinkle score was 5.48. At the 6-month follow-up the average score was 3.47. The overall average change in score from pre-treatment to post-treatment was 1.97. Subject self-assessment at 6 months indicated that 90% of subjects were extremely or satisfied with their results. Unanticipated adverse events were absent with anticipated post-treatment erythema lasting for just several hours.

Conclusions: A novel diffractive lens array used with a picosecond 755 nm alexandrite laser for treatment of wrinkles is highly effective and safe for wrinkles and other signs of photoaging. *Lasers Surg. Med.* 49:40–44, 2017.

© 2016 The Authors. *Lasers in Surgery and Medicine* Published by Wiley Periodicals, Inc.

Key words: photoaging treatment; skin pigmentation; picosecond; picosecond laser; prospective clinical trial; laser; diffractive lens array

INTRODUCTION

Photoaging of the skin includes textural changes, wrinkles, and pigment alterations which have been reported to be improved by ablative and non-ablative

fractional lasers [1]. Non-ablative fractional resurfacing allows for rapid healing, rapid clearance of redness with minimal to no injury of the epidermis resulting in improvement in texture, wrinkling, and pigmentation, often seen months later [2].

A picosecond 755-nm alexandrite laser has been reported to be effective in removing tattoo pigment compared to the nanosecond domain lasers [3]. We report the use of picosecond domain with a lens modification for skin rejuvenation, particularly for wrinkles. The picosecond pulse duration domain is 10 times shorter than the commercially available q-switched nanosecond domain. Use of picosecond domain pulses creates mechanical stress which is more than with the nanosecond domain. The shorter picosecond pulse domain duration takes advantage of photomechanical impact for greater possibility of shattering ink or pigment [4].

A diffractive lens array hand piece was recently developed for a 755 nm picosecond laser. This diffractive lens array is capable of delivering laser energy as apexes of high-fluence regions surrounded by low-fluence regions [5]. The diffractive lens array also referred to as a Focused Lens Array (FOCUS) is comprised of over a hundred micro lenses per square centimeter which redistribute the picosecond pulse into highly concentrated beams, surrounded by a lower fluence background (Fig. 1).

This is an open access article under the terms of the Creative Commons Attribution-NonCommercial License, which permits use, distribution and reproduction in any medium, provided the original work is properly cited and is not used for commercial purposes.

Conflict of Interest Disclosures: All authors have completed and submitted the ICMJE Form for Disclosure of Potential Conflicts of Interest and have disclosed the following: RAW and DHM are consultants, researchers and speakers for Cynosure. Research funding was provided for this study.

This study was presented as an oral presentation at the 35th ASLMS annual conference in Orlando, FL and invited for submission to LSM.

*Correspondence to: Robert A. Weiss, MD, 54 Scott Adam Road, Suite 301, Hunt Valley, MD 21030.


E-mail: rweiss@mdlsv.com

Accepted 7 August 2016

Published online 29 September 2016 in Wiley Online Library (wileyonlinelibrary.com).

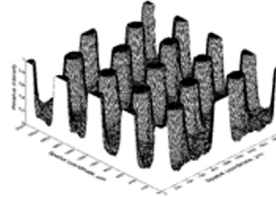
DOI 10.1002/lsm.22577

Diffractive Lens Array (FOCUS)



**Hexagonal close packed
diffractive lens array**
500µm center-to-center
6mm irradiated diameter
0.7 J/cm² average fluence
**25mm lens array to skin
distance**

- 70% of total energy is delivered through the micro-spots; remaining 30% results in low fluence background
- Less than 10% of the tissue is exposed to ultra high fluence



Fluence distribution created on the skin surface

Fig. 1. Diffractive lens array.

Previous reports have indicated that the picosecond 755-nm alexandrite laser using a diffractive lens array may be effective for reduction of facial wrinkles and photodamage [6,7]. The primary purpose of this prospective study was to evaluate the efficacy and safety of the treatment of wrinkles, including peri-oral and -ocular, using a diffractive Focused Lens Array (FOCUS) picosecond 755 nm alexandrite laser as well as observation of other symptoms of photoaging.

MATERIALS AND METHODS

This prospective, blinded study evaluated the efficacy and safety of the treatment of peri-oral and -ocular wrinkles using a diffractive lens array coupled with a picosecond domain 755 nm alexandrite laser (PicoSure[®], Cynosure, Westford, MA). Secondary data points were changes in dyspigmentation and overall patient satisfaction as required by the US FDA. This study was conducted at the McDaniel Institute of Anti-Aging Research and at the Maryland Laser, Skin, and Vein Institute, LLC, and followed the general guidelines recommended in current Good Clinical Practices and conducted under IRB supervision.

Forty Caucasian female subjects were enrolled with average age of 58, ranging from 47 to 64 years of age. Eight five percent of subjects were Fitzpatrick skin types II and III; four subjects were skin type I and two subjects were skin type IV.

Eligible subjects had to be healthy non-smokers between 18 and 65 years old and have a Fitzpatrick wrinkle scores of 4–7. Subjects had to be willing to consent to participate in the study, to comply with all requirements of the study including biopsies, being photographed, and attending all treatment and follow up visits.

Six subjects in this cosmetic study consented to biopsy at 1, 3, and 6 months post-treatment. Subjects received four

full face treatments at 1 month intervals. A 6 mm spot size diffractive lens array delivered treatment fluence of 0.71 J/cm², at each focal point using 10 Hz pulse repetition at a pulse duration of 750 picoseconds. Four passes for a total of 5,000 pulses were delivered during each treatment. For the subjects who underwent biopsies, 2 mm punch biopsies from periorbital areas were performed. Digital photographic images were taken at 1, 3, 4, and 6 months post-treatment. Photographic images were captured utilizing the VISIA imaging system (Canfield Scientific, Newark, NJ). Photographs were taken from three angles full frontal (0°) and at profile from the left (45°) and from the right side (–45°). Images were graded by blinded physician laser experts rating fine lines/wrinkles, erythema, dyschromia, and global improvement at baseline, 1, 3, and at 6 months. Histological data based on the biopsies described above was also analyzed.

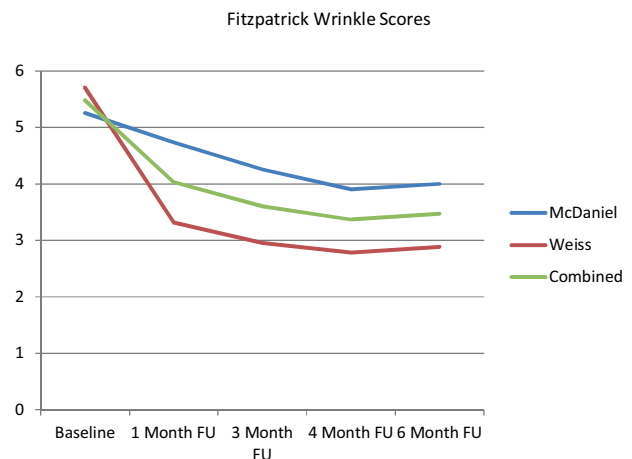


Fig. 2. Improvement in Fitzpatrick wrinkle scores.

The subjects were asked to complete a diary tracking their evaluation of their comfort levels following treatments 3 and 4 and to fill out a questionnaire at their final visit. Patient diary data was used to record adverse events. All adverse experiences, whether or not considered related to the product application, were recorded. Investigator and subject satisfaction were recorded on a questionnaire and physician rated global improvement was recorded using a global aesthetic improvement scale (GAIS).

The grading of wrinkles was based on the Fitzpatrick Wrinkle Scale [8]. Global improvement, a qualitative assessment of the overall condition of the skin from no improvement in photodamage (grade 0) to significant improvement in photodamage (grade 4) was a combination score that included fine lines/wrinkles, dyschromia, and erythema. With regard to the evaluation of pigment/dyschromia, blinded graders were asked to correctly identify post-treatment images from baseline images, placed in random order.

Treating physicians graded overall subject improvement on a 5-point scale from 5 to 1 (5 = worse, 4 = no change, 3 = improved, 2 = much improved, 1 = very much improved). As required by the US FDA for this registry study, subjects rated their overall satisfaction on a 4-point scale, 0–3, (3 = extremely satisfied, 2 = satisfied, 1 = dissatisfied, 0 = extremely dissatisfied) and how likely they would be to recommend the treatment to a friend or family member on a 4-point scale, 0–3, (3 = extremely likely, 2 = likely, 1 = unlikely, 0 = extremely unlikely).

RESULTS

At baseline the average Fitzpatrick wrinkle score was 5.48. At the 6-month follow-up the average score improved to 3.47 ($P < 0.05$). A lower score indicates less wrinkles. The overall average change in score from pre-treatment to post-treatment was 1.97. A graphic representation of the

Blinded Photo Scoring

Pre-treatment baseline = 0

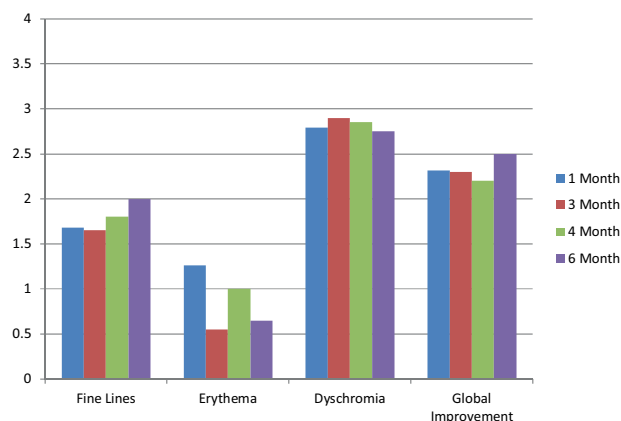


Fig. 3. Blinded Photoscoring for four categories (0 = None, 1 = Mild, 2 = Moderate, 3 = Marked, 4 = Significant).

improvement in Fitzpatrick wrinkle scores is shown in Figure 2.

Blinded photo review by expert physician graders of fine lines, erythema, dyschromia, and global improvement was performed using a scale of 0 = None, 1 = Mild, 2 = Moderate, 3 = Marked, 4 = Significant. This data is summarized in Figure 3. At 6 months improvement from baseline was for fine lines moderate (average = 2), erythema less than mild (average = 0.65), dyschromia was high moderate (average = 2.75), and for global improvement mid moderate (average = 2.5). Blinded expert physician photo graders evaluating images placed in random order were able to correctly identify the post-treatment photo at a significant rate of 82% (93/114). Examples of clinical improvement are shown in Figures 4 and 5.

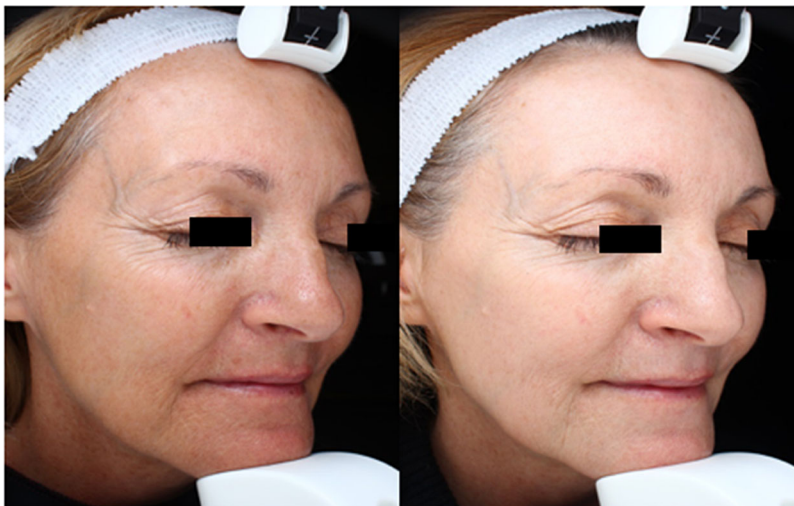

Fig. 4. Typical clinical result after three treatments 1 month apart. Notice reduction of fine lines, improved overall texture, and improvement in pigmentation. This patient was very satisfied with her treatment.

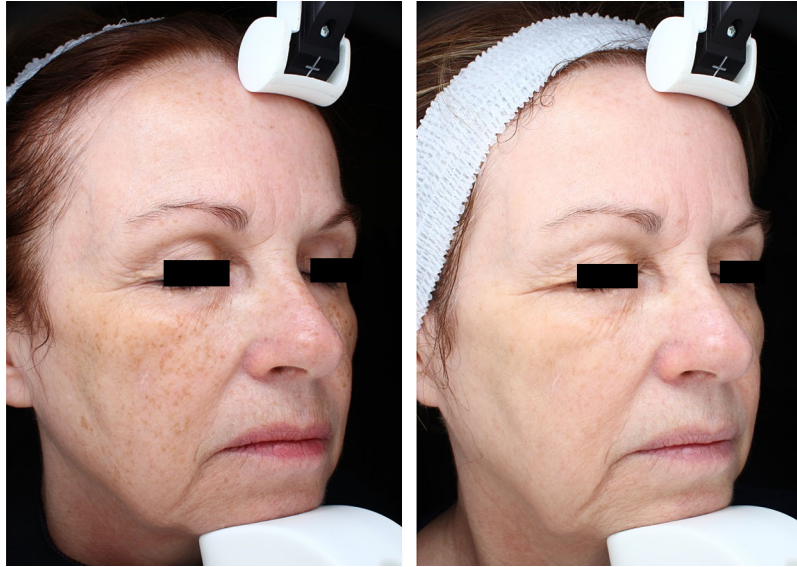

Fig. 5. Another clinical result of reduced in fine wrinkles with textural and color improvement.

At 1 and 6 months for treating physician satisfaction ratings, 97.4% were extremely satisfied or satisfied and 89.5% were extremely satisfied or satisfied, respectively, with the overall patient results. At 6 month assessment according to physician review, improvement scores were 31.6% of subjects were very much improved, 28.9% were much improved, and 28.9% were improved (total of 89%).

Subject satisfaction (required by US FDA) indicated that 42.1% and 47.4% of patients were extremely satisfied and satisfied, respectively, with their results. This was sustained at 6-month follow-up where 36.8% and 57.9% of patients were extremely satisfied and satisfied, respectively. In addition, at 1 month 42.1% were extremely likely and 44.7% were likely to recommend the treatment. This was sustained at 6-month follow-up, where 42.1% were extremely likely and 44.7% were likely to recommend the treatment, consistent with the subject satisfaction scores.

Serial punch biopsies were taken at baseline and at 1, 3, and 6 months post-final treatment. The biopsies were fixed in 10% buffered formalin, sectioned five microns thin and stained using Hematoxylin and Eosin, Masson Trichrome and Verhoeff stains. At 1 month, mild vacuolization is noted at the basal layer of the keratinocytes. Relative to the baseline biopsies, there was increased dermal collagen (greater volume and more densely spaced) with normal architecture and an increase fine, fibrillar elastin fibers, with a mild inflammatory perivascular infiltrate. Matrix proteins had a more uniform distribution throughout the dermis. At 3 months, the histology remained inflammatory infiltrate free with no noted disruption in melanin. Collagen architecture continued the trend of increased density. Elastin fibers showed increased thickness as well as density. At 6 months the histology showed significant increases in dermal collagen, which was more evident in the mid and lower dermis; but was increased throughout

the full thickness of the samples. Elastin fibers appeared thicker and denser in the upper dermis; but was also evident throughout the sections. Sample histology correlated with improved appearance of photodamage with reduction in wrinkles and improved skin color and texture.

Adverse events were mild and all resolved without permanent sequelae. Expected consequences included redness lasting for several hours, with only one patient reporting erythema lasting for 2 days. One patient reported edema lasting for 4 days. Bruising occurred in one patient. No serious adverse events were reported.

DISCUSSION

This prospective study of 40 subjects documented results of a novel picosecond domain 755 nm alexandrite laser utilizing a novel diffractive lens array for treatment of signs of photoaging including fine wrinkles. The use of a diffractive lens array creates microthermal zones of destruction in the epidermis. Significantly, reduced downtime is an advantage of the diffractive lens array. The majority of patients had resolution of redness less than 24 hours after treatment. This picosecond 755-nm alexandrite laser was found to be very effective in treating wrinkles which was confirmed by Fitzpatrick wrinkle scale assessment and blinded physician assessment. Blinded physician photographic assessments also indicated significant improvement in dyschromia, as well as fine lines. Patient self-assessments indicated high satisfaction with the treatment and subjects were very likely to recommend the treatment. Histologic data adds strong evidence to the textural improvement noted by both patients, blinded expert physician graders and treating physicians. Improvement in scars and texture has been reported with picosecond domain lasers and our findings are entirely consistent [9].

CONCLUSION

A novel diffractive lens array used with a picosecond domain 755 nm alexandrite laser is highly effective and safe for wrinkles and other signs of photoaging. Clinical signs are associated with histologic findings of increased collagen and elastin.

REFERENCES

1. Brauer JA, McDaniel DH, Bloom BS, Reddy KK, Bernstein LJ, Geronemus RG. Nonablative 1927nm fractional resurfacing for the treatment of facial photopigmentation. *J Drugs Dermatol* 2014;13:1317–1322.
2. Geraghty LN, Biesman B. Clinical evaluation of a single-wavelength fractional laser and a novel multi-wavelength fractional laser in the treatment of photodamaged skin. *Lasers Surg Med* 2009;41:408–416.
3. Saedi N, Metelitsa A, Petrell K, Arndt KA, Dover JS. Treatment of tattoos with a picosecond alexandrite laser: A prospective trial. *Arch Dermatol* 2012;148:1360–1363.
4. Freedman JR, Kaufman J, Metelitsa AI, Green JB. Picosecond lasers: The next generation of short-pulsed lasers. *Semin Cutan Med Surg* 2014;33:164–168.
5. Tanghetti EA. The histology of skin treated with a picosecond alexandrite laser and a fractional lens array. *Lasers Surg Med* 2016. doi: 10.1002/lsm.22540 PubMed PMID: 27252086.
6. Weiss RA, Weiss MA, Beasley K. Picosecond laser for reduction of wrinkles. American Society for Laser Medicine and Surgery Annual Meeting: Phoenix Convention Center/Phoenix, Arizona 2014.
7. McDaniel DH. Treatment of facial photodamage and rhytides using a picosecond pulsed alexandrite laser and specially designed focus optic. American Society for Laser Medicine and Surgery Annual Meeting: Phoenix Convention Center/Sheraton Phoenix Downtown Hotel, Phoenix, Arizona 2014.
8. Shoshani D, Markovitz E, Monstrey SJ, Narins DJ. The modified Fitzpatrick Wrinkle Scale: A clinical validated measurement tool for nasolabial wrinkle severity assessment. *Dermatol Surg* 2008;34:S85–S91; discussion S.
9. Brauer JA, Kazlouskaya V, Alabdulrazzaq H, Bae YS, Bernstein LJ, Anolik R, Heller PA, Geronemus RG. Use of a picosecond pulse duration laser with specialized optic for treatment of facial acne scarring. *JAMA Dermatol* 2015; 151(3):278–284.